



MR Report

Patient Name	ABHIRAJ	Patient ID	HGUR-350024795
Age/ Sex	4M / M	Service Name	MRI Head Without Contrast
Accession No.	1238107-879	Scan Date Time	01-10-2024 23:26:02
Referred By	Dr Renu	Report Date Time	04-10-2024 09:48

INVESTIGATION : MRI BRAIN

SEQUENCES OBTAINED USING A 1.5 TESLA SUPER CONDUCTING MRI UNIT

High-resolution SE-T1W, FSE-T2W, FLAIR & GRE-T2* sections in the axial plane. FRFSE-T2W sections in the sagittal & coronal planes. Diffusion imaging was also performed at B value 1000.

Clinical Indications:- Post caesarean

Prior Imaging:- None

Findings:-

The study reveals severe non-communicating hydrocephalus (Evans index 0.69); with massive dilation of both lateral ventricles such that most of the supratentorial compartment is now occupied by fluid filled lateral ventricles. There is marked effacement of residual parenchyma along the calvarium. Only minimal normal appearing parenchyma is present in the lower right temporal region. There is marked dilatation of third ventricle and its recesses. Prominent bilateral temporal horn is noted.

The fourth ventricle appears normal with midline location. No obstructing mass is seen. The brainstem and cerebellum appear normal.

The cerebellar tonsils are normally positioned. Limited evaluation of orbits does not reveal any significant abnormality.

IMPRESSION:

The study reveals severe non-communicating hydrocephalus (Evans index 0.69); with massive dilation of both lateral ventricles such that most of the supratentorial compartment is now occupied by fluid filled lateral ventricles. There is marked effacement of residual parenchyma along the calvarium. Only minimal normal appearing parenchyma is present in the lower right temporal region. There is marked dilatation of third ventricle and its recesses. Prominent bilateral temporal horn is noted.

N.B. : This is only a professional opinion and not the final diagnosis. Radiological investigations are subject to variations due to technical limitations. Hence, correlation with clinical findings and other investigations should be carried out to know true nature of illness.

HOSPITAL NO: HGUR-350024795

REPORT TIME: 04-10-2024 09:48

HealthMap Diagnostics Private Limited

Reg. Off. : The Annexe, 98/2, Rustom Bagh, HAL Airport Road, Bengaluru - 560 017, Karnataka, India
P +91 80 4936 0300 F +91 80 4936 0395, www.manipaltrutest.com
Corporate Off.: DSM 236-237, DLF Tower, Shivaji Marg, New Delhi - 110 015, P + 91 11 4576 8138
CIN : U85110KA2015PTC079665
CT - MRI Centre Gurugram : 7082111726, 7082403242, 7082111728 Toll Free : 1800 2121 805
E-mail : gurgaoncentre@manipaltrutest.com

24X7 Working. Services Available
on Sunday and Holidays

Awarded the most coveted
NABH ACCREDITATION
by Quality Council of India
Amongst the first as
PPP MIC Centre in the country




		MR Report	
Patient Name	ABHIRAJ	Patient ID	HGUR-350024795
Age/ Sex	4M / M	Service Name	MRI Head Without Contrast
Accession No.	1238107-879	Scan Date Time	01-10-2024 23:26:02
Referred By	Dr Renu	Report Date Time	04-10-2024 09:48

These findings possibly represent gross hydrocephalus likely due to underlying aqueductal stenosis.

Advice: Clinical / lab parameter correlation.

This is a professional opinion and not diagnosis. Please correlate clinically & with other investigations. This report is not valid for medico legal purposes.



Dr. Divya Nijhawan
Consultant Radiologist
M.B.B.S., MD

N.B. : This is only a professional opinion and not the final diagnosis. Radiological investigations are subject to variations due to technical limitations. Hence, correlation with clinical findings and other investigations should be carried out to know true nature of illness.

HOSPITAL NO: HGUR-350024795

REPORT TIME: 04-10-2024 09:48

HealthMap Diagnostics Private Limited

Reg. Off. : The Annexe, 98/2, Rustom Bagh, HAL Airport Road, Bengaluru - 560 017, Karnataka, India
P +91 80 4936 0300 F +91 80 4936 0395, www.manipaltrutest.com
Corporate Off.: DSM 236-237, DLF Tower, Shivaji Marg, New Delhi - 110 015, P + 91 11 4576 8138
CIN : U85110KA2015PTC079665
CT - MRI Centre Gurugram : 7082111726, 7082403242, 7082111728 Toll Free : 1800 2121 805
E-mail : gurgaoncentre@manipaltrutest.com

24X7 Working. Services Available
on Sunday and Holidays

Awarded the most coveted
NABH ACCREDITATION
by Quality Council of India
Amongst the first as
PPP MIC Centre in the country

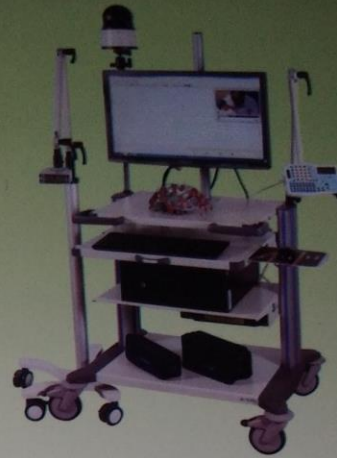

Neuroflux

Neurology Clinic & Neurodiagnostic Center
The Neurodiagnostic Specialist

NEUROPHYSIOLOGY TEST

- ❖ AWAKE EEG, SLEEP EEG
- ❖ PROLONGED VIDEO EEG
- ❖ BERA / OAE TEST
- ❖ VEP TEST
- ❖ NCV / EMG TEST



NEUROPSYCHOLOGICAL TESTING:-

- IQ ASSESSMENT • AUTISM SCREENING TESTING
- DYSLEXIA SCREENING TEST • LEARNING DISABILITY SCREENING TEST

PATHOLOGY TEST & GENETIC TESTING

Our Specialities :



Pediatric Neurology

Dr. Ajit Singh Baghel

MD, DNB (PEDIATRICS), FELLOWSHIP IN PEDIATRIC NEUROLOGY.

EX. SR. PGIMER CHANDIGARH (PEDIATRIC NEUROLOGY.)

Consultant Pediatric Neurologist at Artemis Hospital, Gurugram

NEURO FLUX NEUROLOGY CENTER & NEURODIAGNOSTIC CENTER

Address:- First Floor, Opp: Modern Diagnostic
& Lall Nursing Home, New Railway Rd, Gurugram, Haryana 122021

Contact no. +91-9920223520 / 74283 69777



neurofluxneurology@gmail.com



www.neuroflux.in

DR. AJIT SINGH BAGHEL

MD (Peds, Wadia), DNB (Peds)
Fellowship in Pediatric Neurology (Pune)
Ex PGIMER Chandigarh SR (Peds Neurology)
Consultant Pediatric Neurologist, Artemis Hospital, Gurugram
Mob. : 9920223520



Neuroflux

Neurology Clinic & Neurodiagnostic Center
The Neurodiagnostic Specialist

Name: Mast Abhiraj (M , 17 Weeks)

Date & Time: 04-Oct-2024; 06:18 PM

Contact : +91-8826628246

Patient ID: IUZ1EH16WBCO

CHIEF COMPLAINTS: c/o large size head since the age of 2 months, birth history - FT/LSCS/CIAB , no complication, irritable behavior, intermittent vomiting +. HC=45.5cm , large tense fontanale, MRI s/o obstructive hydrocephalus (aqueductal stenosis)

DIAGNOSIS: obstructive hydrocephalus

Rx

SI	Medicine Name	Regime and Instruction
1	DIAMOX TAB ACETAZOLAMIDE (250MG)	0 - 0 - 1/4 for 21 days

210 / 4

ADVICE:

- vp shunt to be done after neuro-surgeon opinion

Dr. Ajit Singh Baghel
MD, DNB (Peds)
Fellowship in Pediatric Neurology
Consultant - Pediatric Neurologist
Neuroflux Neurology Center,
New Railway Road, Gurugram-122001
M. : 9920223520
Regn. No. : HMC-011933, MCI-10/366649
Dr. Ajit Singh Baghel

{ Dr. Anurag Sharma.
9560703163 }

Ped. Neuro-surgery

Ambala Hospital

Fairdabad.

First Floor, New Railway Road, Near Chand Gas Agency, Exact Opp. Modern Diagnostc, Gurugram-122001 Haryana

Neurodiagnostic Center Branches :

GURUGRAM 9920223520 | PANIPAT 7428369777 | MATHURA 8755657097

✉ neurofluxneurology@gmail.com | 🌐 : www.neuroflux.in

follow us :

7/10/24

MRD

Master Asthooj

17 weeks / male

Hydrocephalus ? Agredent stenosis

- Twin delivery, CS, @ 38-39 weeks.
- Delayed cried ~~immediately after birth~~ after birth as per notes / NO H/O meningitis
- ↑ in head size since 2 mths
- HC - 45.5 cm
- Smart baby (+)
- AF - tense
- WT - 3.6 kg.

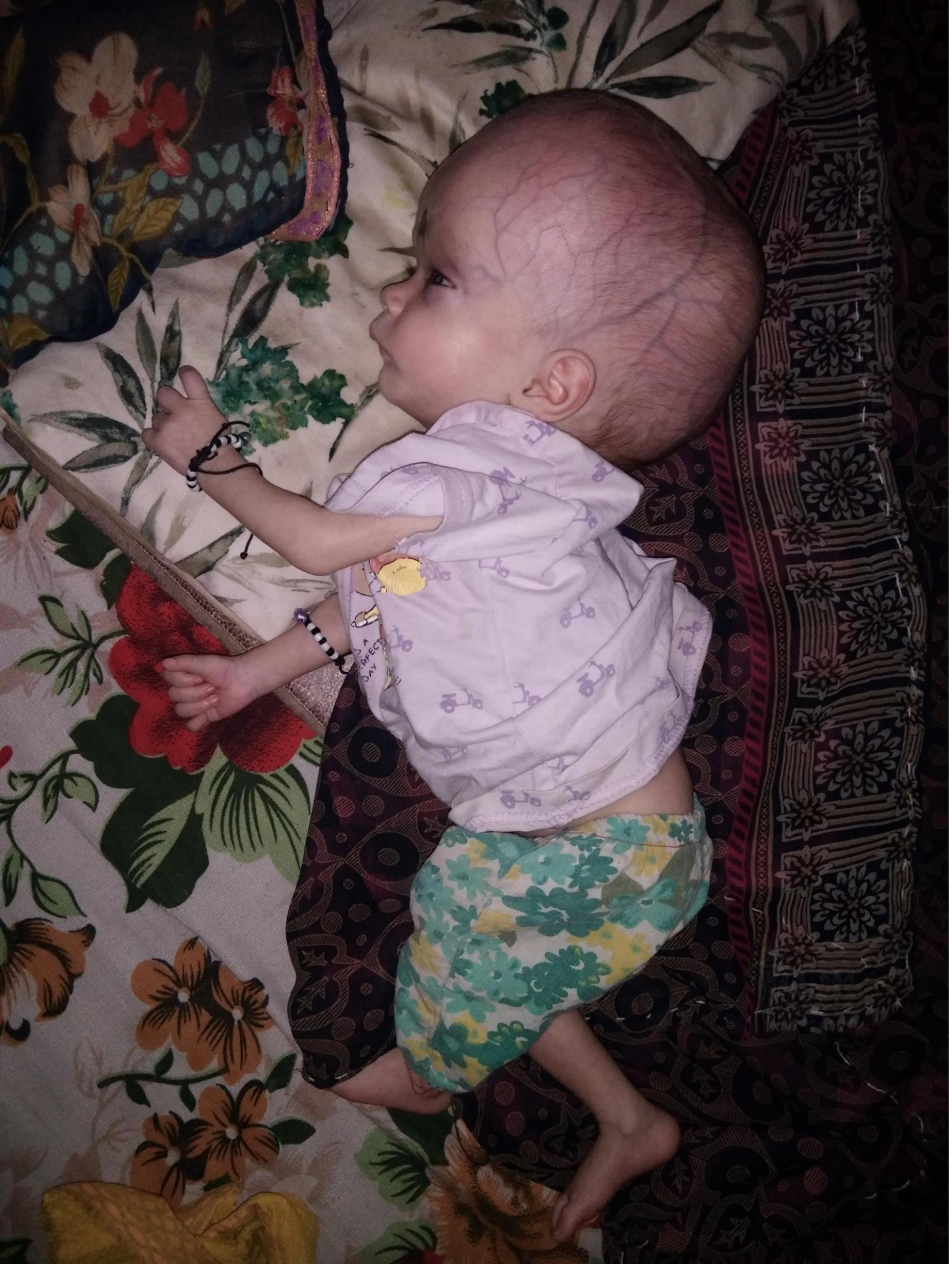Na+Ked
Obstetric gross
HCL.

Ad / Need VP shunt. to GA

Paediatric echo

CBC / KFT / Visual markers / PT-INR
↓
HIV / HBsAg / HCV.


Dr. Sachin Gupta
Senior Consultant, Assistant Professor
Neuro Surgery
Amrita Institute of Medical Sciences
& Research Centre, Faridabad
Reg. No. HN21839





भारत सरकार

Government of India



रीतु देवी

Ritu Devi

जन्म तिथि/ DOB: 01/01/1992

महिला / FEMALE



7482 7274 1021

मेरा आधार, मेरी पहचान

Issue Date: 28/02/2015



भारत सरकार
Government of India

गणेश कुमार
Ganesh Kumar
जन्म तिथि/DOB: 01/01/1987
लिंग/ MALE



4720 4989 9598

VID : 9106 1306 8911 1944

भारत आवास, सेवा परामर्श